CHAPTER
42 Musculoskeletal tumours

Learning objectives

- List the symptoms and signs associated with a musculoskeletal tumour
- Understand why a patient with a suspected musculoskeletal tumour should be referred to a specialist centre for staging, biopsy and multidisciplinary management
- Understand why staging should be completed before biopsy
- Explain why a diagnosis is required before treatment
- Understand the principles of biopsy
- Describe the principles of surgical treatment of musculoskeletal tumours
- List the aims of surgical treatment for metastatic bone disease
- Understand how to manage patients with an impending or completed pathological fracture
- Evaluate the risk of pathological fracture

INTRODUCTION

Musculoskeletal tumours include primary and secondary benign and malignant tumours of bone and soft tissue. The most common malignant tumours in bone are metastatic carcinomas (*Figure 42.1*). Advances in oncological treatment mean that the number of patients living with metastatic bone disease is increasing. The most common carcinomas that metastasise to bone originate in the breast, prostate, lung, kidney, thyroid and colon (*Figure 42.2*).

Haematopoietic tumours may also arise in bone: multiple myeloma (*Figure 42.3*) is a malignant neoplasm arising from plasma cells in the bone marrow, leading to multiple lesions in the skeleton. When solitary, this type of tumour is called a plasmacytoma.

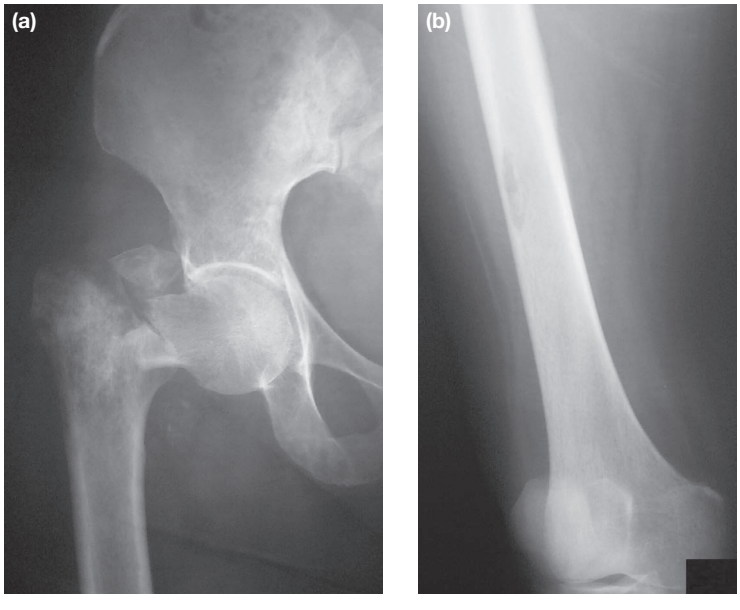

Figure 42.1 (a) Pathological fracture of the proximal femur through metastatic breast carcinoma. **(b)** Radiographs of the whole femur show a further, more distal metastatic deposit.

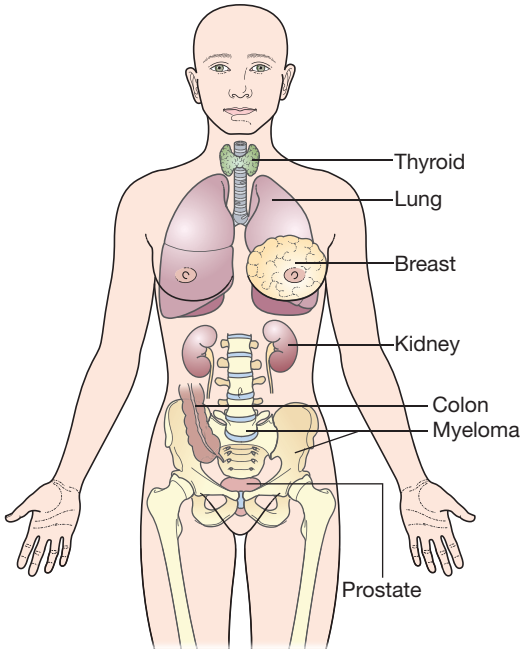

Figure 42.2 Common malignant tumours involving bone (courtesy of Mr Andy Biggs, The Robert Jones and Agnes Hunt Orthopaedic Hospital NHS Foundation Trust).

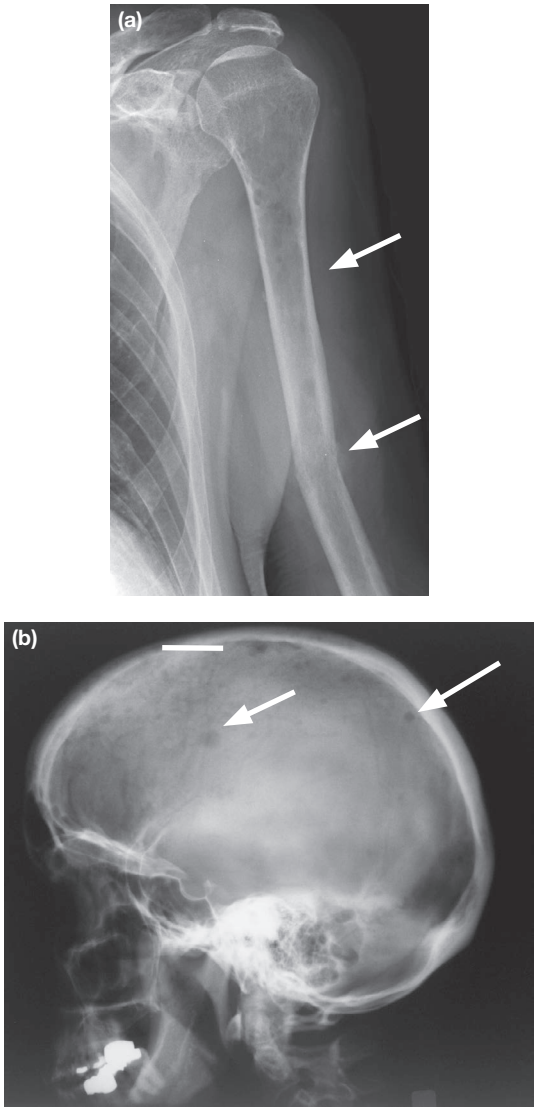

Figure 42.3 (a) Multiple myeloma affecting the left humerus with a pathological fracture (arrows). (b) Multiple myeloma with multiple deposits in the skull (arrows).

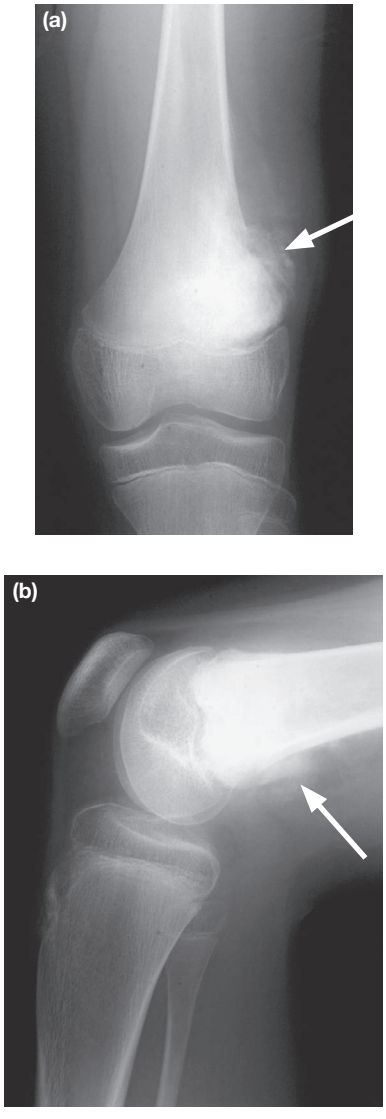

Figure 42.4 (a, b) Sclerotic osteosarcoma of the distal femur in a child (arrows).

Malignant primary bone tumours (sarcomas) are very rare, but notably can occur in children and young adults. The most common malignant primary bone tumours are osteosarcoma (*Figure 42.4*), chondrosarcoma (*Figures 42.5, 42.6 and 42.7*) and Ewing's sarcoma (*Figure 42.8*).

Soft-tissue tumours are common. However, only one in a 100 is malignant (*Figure 42.9*).

BONE TUMOURS

Tumours found in bone are classified according to their morphological appearances. These include:

- metastatic carcinomas; may show histological features of their tissue of origin;
- haematopoietic tumours; e.g. myeloma;
- osteogenic tumours; e.g. osteosarcoma;
- chondrogenic tumours; e.g. chondrosarcoma;
- others; e.g. Ewing's sarcoma.

Osteosarcoma has two age incidence peaks: one in adolescence and the other later in life. Osteosarcomas in older patients usually arise in association with Paget's disease, osteonecrosis or after radiotherapy treatment. Ewing's sarcoma occurs in adolescence, whereas the incidence of chondrosarcoma increases from middle age onwards.

Some conditions are associated with an increased likelihood of developing malignant tumours in bone and/or cartilage (*Table 42.1*).

James Ewing, 1866–1943, Professor of Pathology, Cornell University Medical College, New York, NY, USA, described this type of sarcoma in 1921.
Sir James Paget, 1814–1899, surgeon, St Bartholomew's Hospital, London, UK, described osteitis deformans in 1877.

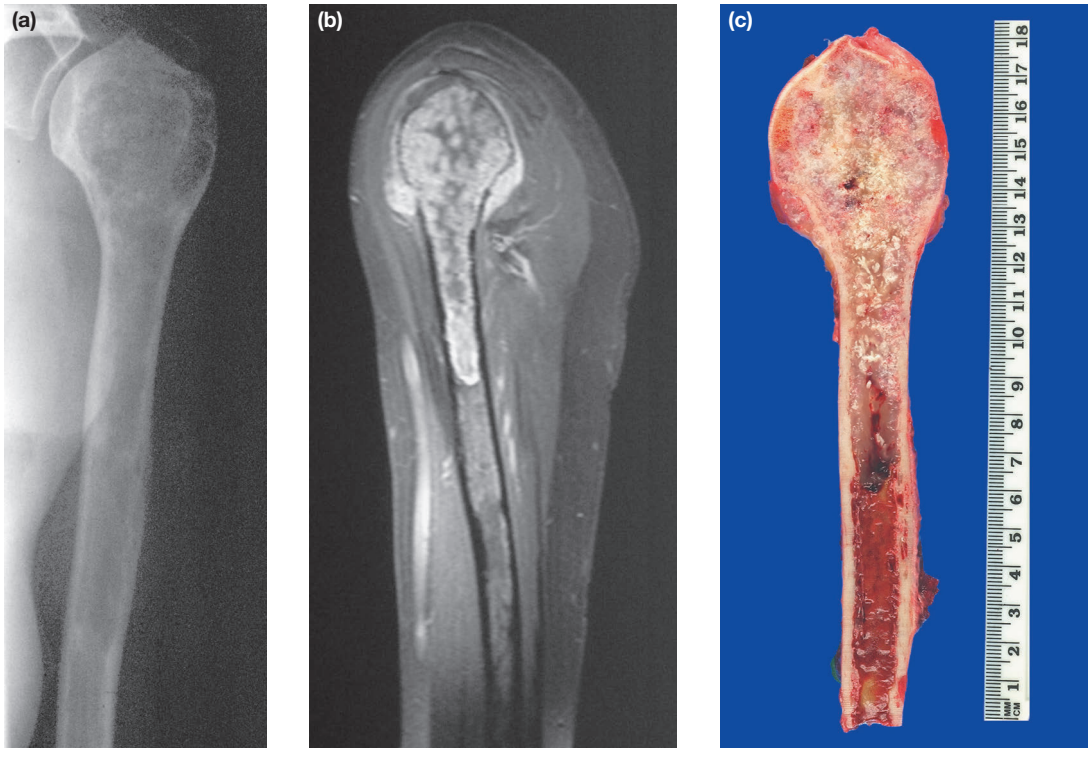

Figure 42.5 (a) Chondrosarcoma of the proximal humerus with multiple calcifications. (b) Magnetic resonance imaging scan showing extensive involvement. (c) Excised chondrosarcoma of the proximal humerus.

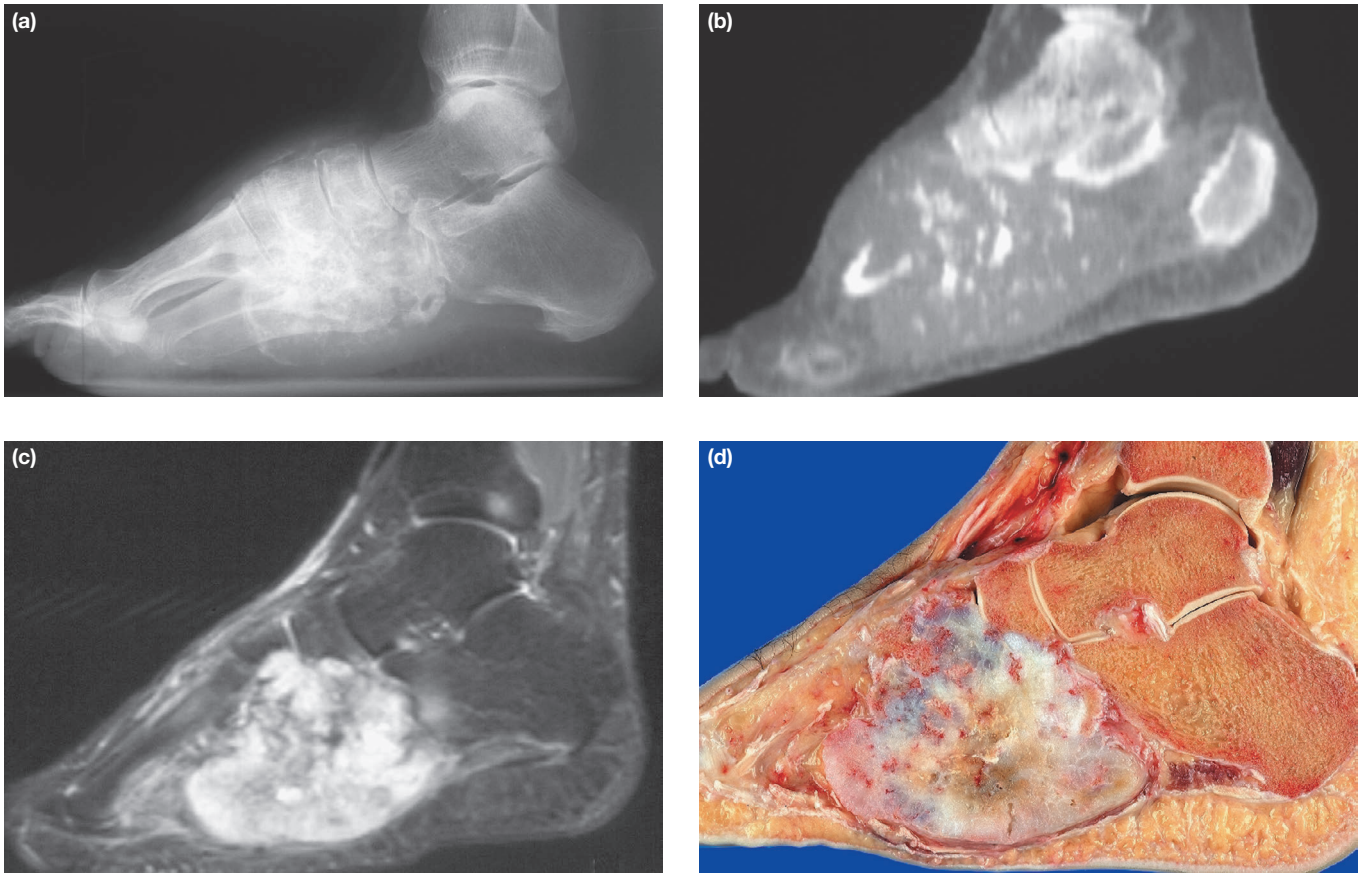

Figure 42.6 (a) Chondrosarcoma of the foot. (b) Computed tomography scan reconstruction showing multiple calcifications. (c) T2-weighted magnetic resonance imaging scan shows high signal in the chondrosarcoma. (d) Excised chondrosarcoma of the foot.

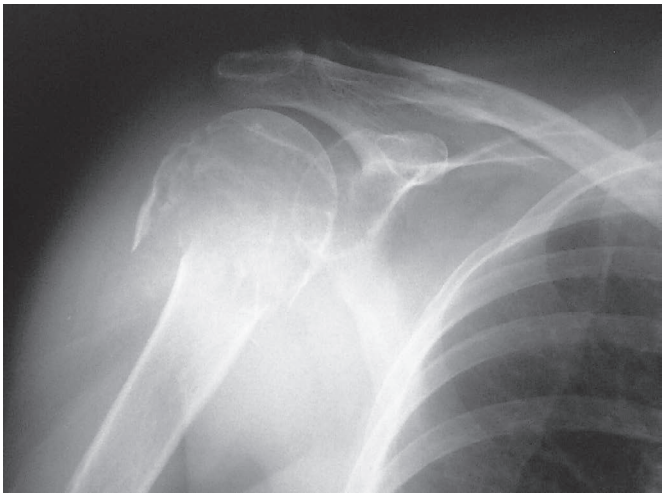

Figure 42.7 Pathological fracture through a primary chondrosarcoma of the proximal humerus.

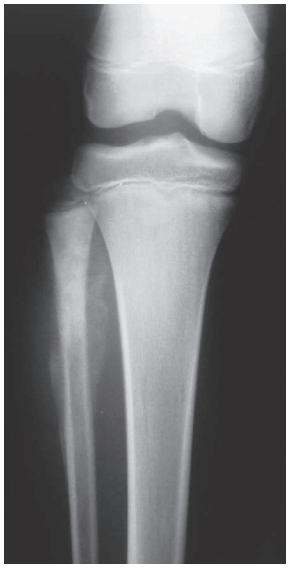

Figure 42.8 Ewing's sarcoma of the proximal fibula. The tumour is metadiaphyseal in location with a periosteal reaction and subtle onion-skinning.

TABLE 42.1 Conditions associated with an increased risk of malignant disease in bone and cartilage.

High risk	Moderate risk	Low risk
Maffucci syndrome (enchondromatosis and angiomas of soft tissue)	Hereditary multiple exostoses	Chronic osteomyelitis
Ollier's disease (enchondromatosis)	Polyostotic Paget's disease	Osteonecrosis
Familial retinoblastoma syndrome	Radiation osteitis	Fibrous dysplasia, osteogenesis imperfecta, osteoblastoma and chondroblastoma

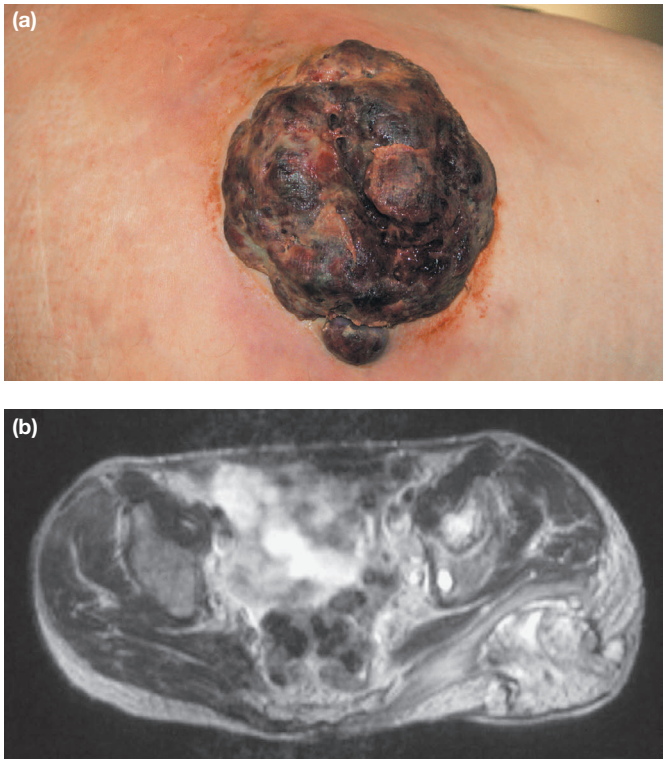

Figure 42.9 (a) Large fungating soft-tissue sarcoma of the buttock. (b) Magnetic resonance imaging scan from the same patient showing a large fungating sarcoma of the buttock.

Metastatic bone disease

Most tumours that metastasise to bone are carcinomas. Sometimes, despite further investigations, the primary tumour is never found: these patients are described as having 'carcinoma of unknown primary'. However, with advanced diagnostics and laboratory investigations the origin of most bone metastases can be identified.

Carcinomas usually spread to bone by the haematogenous route: the spine is the third most common site for metastases, after the lung and liver. Although most patients with metastatic cancer will have bone metastases in the spine before they die, only 10% are symptomatic.

Tumour cells metastasise to the spine via Batson's venous plexus. These retroperitoneal veins have no valves and allow retrograde embolic spread to the spine and proximal long bones (*Figure 42.10*).

Bone metastases can be lytic, sclerotic or mixed. Lytic metastases are usually highly vascular or locally aggressive such that there is no healing response from the bone. Metastases from prostate cancer may appear sclerotic.

Metastases are rare in children, but bone metastases can occur from neuroblastoma, rhabdomyosarcoma and clear cell carcinoma of the kidney.

Angelo Maffucci, 1847–1903, Professor of Pathological Anatomy, Pisa, Italy, described enchondromatosis in association with soft tissue haemangiomas in 1881.
Louis Xavier Edouard Léopold Ollier, 1830–1900, Professor of Surgery, Lyons, France, described enchondromatosis in 1899.
Oscar V Batson, 1894–1979, American otolaryngologist.

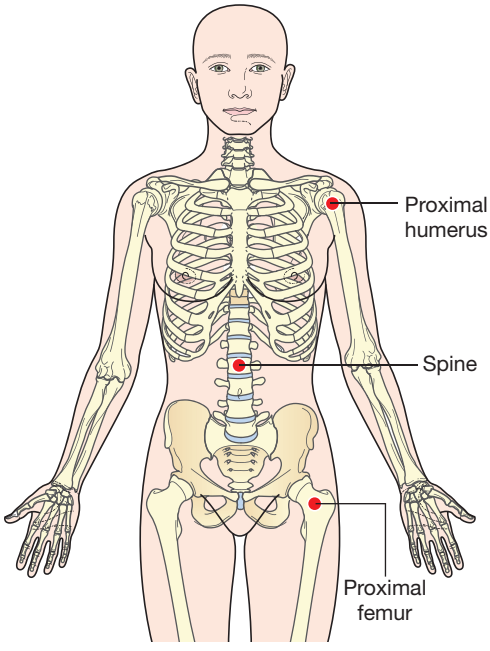

Figure 42.10 Common sites of metastatic bone disease (courtesy of Mr Andy Biggs, The Robert Jones and Agnes Hunt Orthopaedic Hospital NHS Foundation Trust).

Summary box 42.1

Most common tumours metastasising to bone (93%)

- Breast
- Prostate
- Lung
- Renal
- Thyroid
- Colon

Summary box 42.2

Most common sites of bone metastases

- Spine
- Proximal femur and pelvis
- Proximal humerus

Haematopoietic tumours

Malignant haematopoietic tumours that commonly present in orthopaedic clinics are either solitary plasmacytoma/multiple myeloma (arising from plasma cells; *Figure 42.2*) or lymphomas (arising from lymphoid cells).

Osteogenic tumours

These tumours characteristically produce osteoid or bony matrix, which may be seen on imaging studies or on histological examination.

Osteoid osteoma (*Figures 42.11 and 42.12*) is a benign bone-forming lesion that is small but very painful. Usually, pain occurs at night and is typically relieved by non-steroidal anti-inflammatory medication. Osteoid osteomas usually occur in children and adolescents. They can arise in any bone, particularly the proximal femur, and cause a dense cortical reaction in the centre of which is a nidus (*Figure 42.12*).

Figure 42.11 Radiograph showing an osteoid osteoma of the tibial diaphysis with reactive bone formation (arrow).

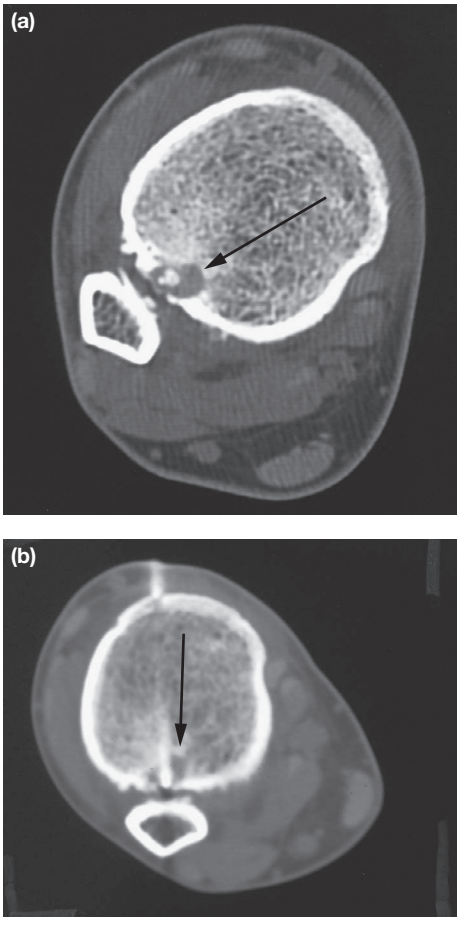

Figure 42.12 (a) Axial computed tomography (CT) scan showing an osteoid osteoma nidus in the distal tibia (arrow). (b) CT-guided radiofrequency thermocoagulation of an osteoid osteoma of the distal tibia. The scan shows the electrode *in situ* (arrow).

Summary box 42.3

Malignant bone tumours

- Plasmacytoma – solitary form of multiple myeloma
- Osteosarcoma – usually secondary to Paget's disease and radiotherapy in older patients
- Chondrosarcoma
- Ewing's sarcoma

Osteoid osteomas can cause irritation and effusions if they occur close to a joint.

Osteoblastoma is the larger (>2 cm), more aggressive counterpart of osteoid osteoma and more typically occurs in the spine.

Osteosarcoma (*Figure 42.4*) is a malignant bone-forming tumour, most common in the distal femur, followed by the proximal tibia, proximal humerus and distal tibia. The radiological and histological classification of osteosarcomas includes sclerotic (*Figure 42.4*), chondroblastic, telangiectatic and other more unusual forms. Usually, osteosarcomas are intraosseous, but they can also arise from the surface of bones. Parosteal osteosarcoma (*Figure 42.13*) is a low-grade osteosarcoma that arises from the surface of the bone, typically of the distal femur or proximal tibia. Symptoms are often mild and longstanding.

Summary box 42.4

Tumours producing bone

- Osteoid osteoma – small, painful; produce dense cortical reaction
- Osteoblastoma – larger and more aggressive than osteoid osteoma
- Osteosarcoma – malignant; commonest in lower femur and upper tibia

Chondrogenic tumours

These tumours produce chondroid matrix and include a wide range of benign and malignant tumours.

Osteochondroma (*Figures 42.14 and 42.15*) is a benign cartilage-capped bony projection, thought to originate from the physis. The bony projection always grows away from the joint towards the diaphyseal region of the bone. It has no structures attached to it. Osteochondromas can be pedunculated (with a stalk) or sessile (without a stalk). The stalk or base is always continuous with the intramedullary cavity of the bone, and the continuity of the cortex of the bone into an osteochondroma is a characteristic radiological feature. They are usually solitary, but some patients have multiple osteochondromas (hereditary multiple exostoses, autosomal dominant inheritance) (*Figure 42.16*). Osteochondromas can cause local irritation and complications include mechanical symptoms, nerve impingement, vascular pseudoaneurysm, fracture and infarction. Increasing size or pain, particularly after skeletal maturity, is concerning and may indicate malignant transformation. The incidence of malignant transformation is less than 1% in solitary osteochondromas and 1–3% in patients with multiple osteochondromas.

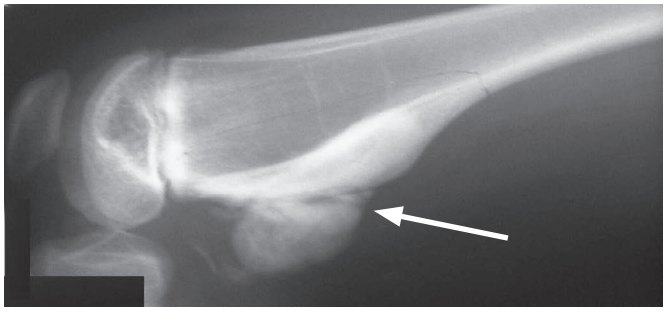

Figure 42.13 Parosteal osteosarcoma of the distal femur in an unusually young patient. There is no continuity between the tumour and the intramedullary cavity of the femur (arrow).

Figure 42.14 Pedunculated osteochondromas (arrow) of the proximal fibula with pseudarthrosis. Osteochondromas always grow away from the physis and are in continuity with the intramedullary cavity of the bone they arise from.

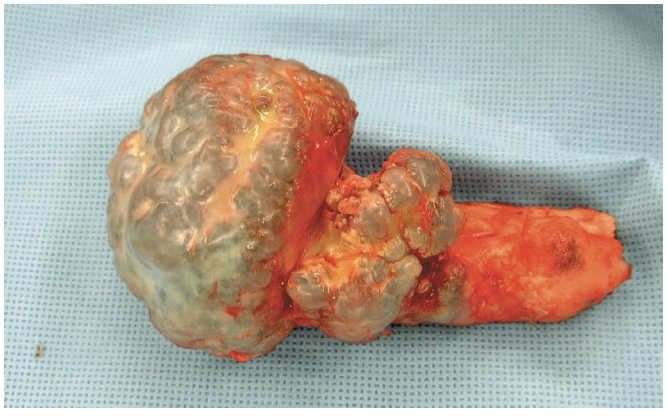

Figure 42.15 Excised pedunculated osteochondroma showing a cartilage cap.

Figure 42.16 Multiple osteochondromas in hereditary multiple exostoses. Note the multiple bone involvement and the flask-shaped femoral metaphyses.

Figure 42.17 (a, b) Calcification and pathological fracture in a benign enchondroma of the proximal phalanx of the ring finger (arrows).

Enchondroma (*Figure 42.17*) is a benign cartilaginous neoplasm within the intramedullary cavity of bone. Approximately 50% are in the hands and feet: enchondromas are the most common bone tumours in the hand. Although they can present with pain, swelling or pathological fracture, many are entirely asymptomatic and are detected incidentally. Patchy calcification, expansion and scalloping can be visible on radiographs, but some are only diagnosed on magnetic resonance imaging (MRI) scan.

Ollier's disease is a developmental condition characterised by multiple enchondromas. In Maffucci syndrome, multiple enchondromas are associated with multiple angiomas. Malignant transformation to chondrosarcoma can occur in approximately 20% of patients with Ollier's disease and is almost inevitable in patients with Maffucci syndrome.

Chondroblastoma (*Figure 42.18*) is a benign cartilage-producing tumour that occurs in the epiphyses of bones in children. It is most common around the knee. Pain is often severe, with associated inflammation and possibly joint effusion. On plain radiographs, there is an often barely visible lytic lesion in the centre of the epiphysis. Previously, the diagnosis was often missed, but this has become less frequent with MRI scanning, which usually identifies the lesion with an intense inflammatory response.

Chondrosarcoma (*Figures 42.5, 42.6 and 42.7*) is a malignant tumour with cartilage differentiation. The biological behaviour ranges from very low-grade lesions to highly aggressive dedifferentiated tumours. Patients usually present with pain and/or swelling and symptoms may be longstanding. Many chondrosarcomas arise in pre-existing lesions such as osteochondromas or enchondromas. Diagnosis of a chondrosarcoma requires clinical, radiological and pathological correlation. Clear cell chondrosarcoma is a rare form of chondrosarcoma that occurs in the epiphysis (*Figure 42.19*).

Summary box 42.5

Tumours producing cartilage

- Osteochondroma – cartilage capped; grows away from physis
- Enchondroma – inside bone; commonest in hands and feet
- Chondroblastoma – in epiphyses of adolescents
- Chondrosarcoma – of varying malignancy

Others

Simple (unicameral) bone cyst (*Figure 42.20*) is a membrane-lined cavity filled with serous fluid within a bone. It usually occurs in the proximal long bones of children. Associated thinning of the cortex of the bone can lead to fracture. Such fractures usually heal with conservative treatment, but the cyst may only partially resolve.

Aneurysmal bone cyst (*Figure 42.21*) is a benign cystic lesion of bone consisting of blood-filled spaces separated by fibrous septa. The lesion is more aggressive than a simple bone cyst and often presents with pain and swelling. Plain radiographs commonly show aggressive features with eccentric expansion of the cortex and an open physis. Scans often show multiple fluid levels (*Figure 42.21b*).

Giant cell tumour of bone (*Figure 42.22*) is a locally aggressive tumour with large osteoclast-like giant cells. It usually occurs between the ages of 20 and 45, after the physes have closed. Giant cell tumour of bone typically extends into the epiphysis of long bones and erodes bone under the articular cartilage, especially around the knee, proximal humerus and distal radius. 'Benign' metastases are rare.

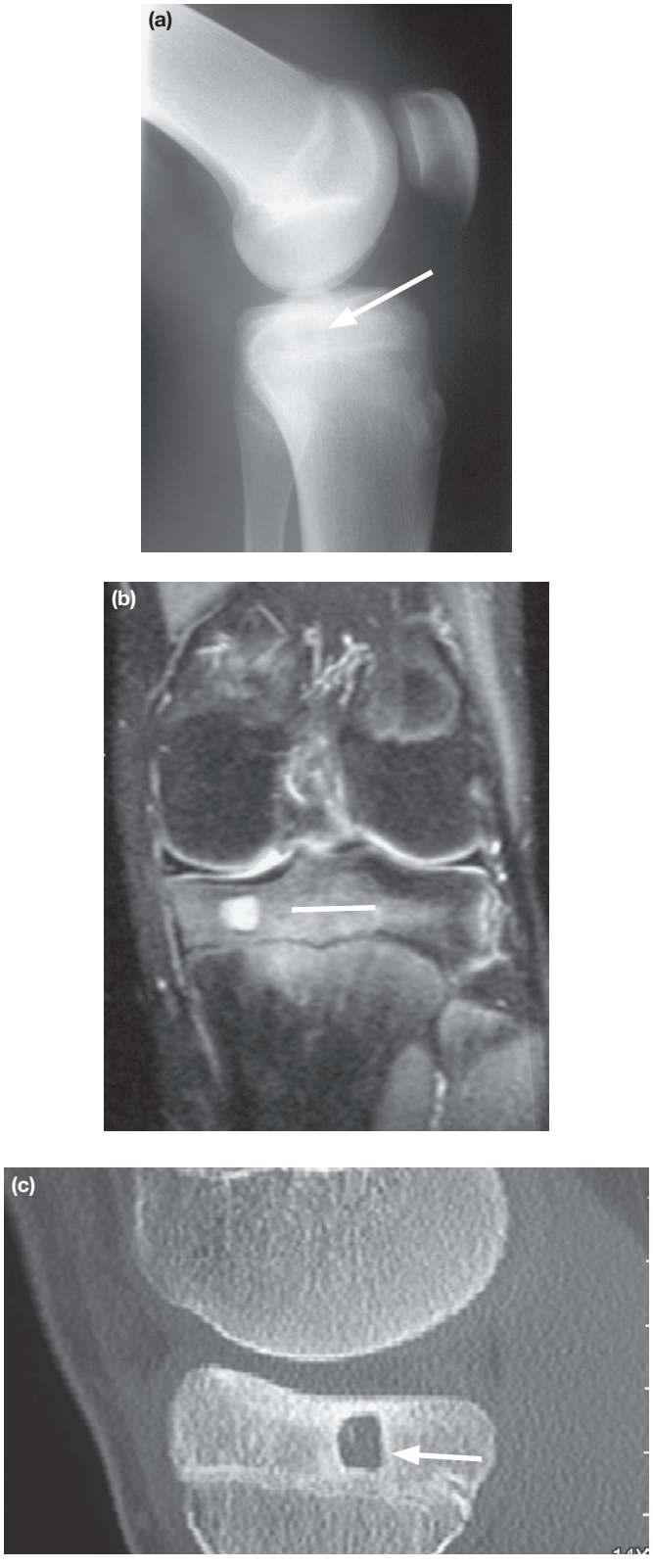

Figure 42.18 (a) Lateral radiograph with a barely visible chondroblastoma in the epiphysis of the proximal tibia (arrow). (b) Coronal T2-weighted magnetic resonance imaging scan showing a chondroblastoma (arrow) in the epiphysis of the proximal tibia with surrounding oedema. (c) Sagittal computed tomography reconstruction showing calcification within a chondroblastoma (arrow) of the proximal tibial epiphysis.

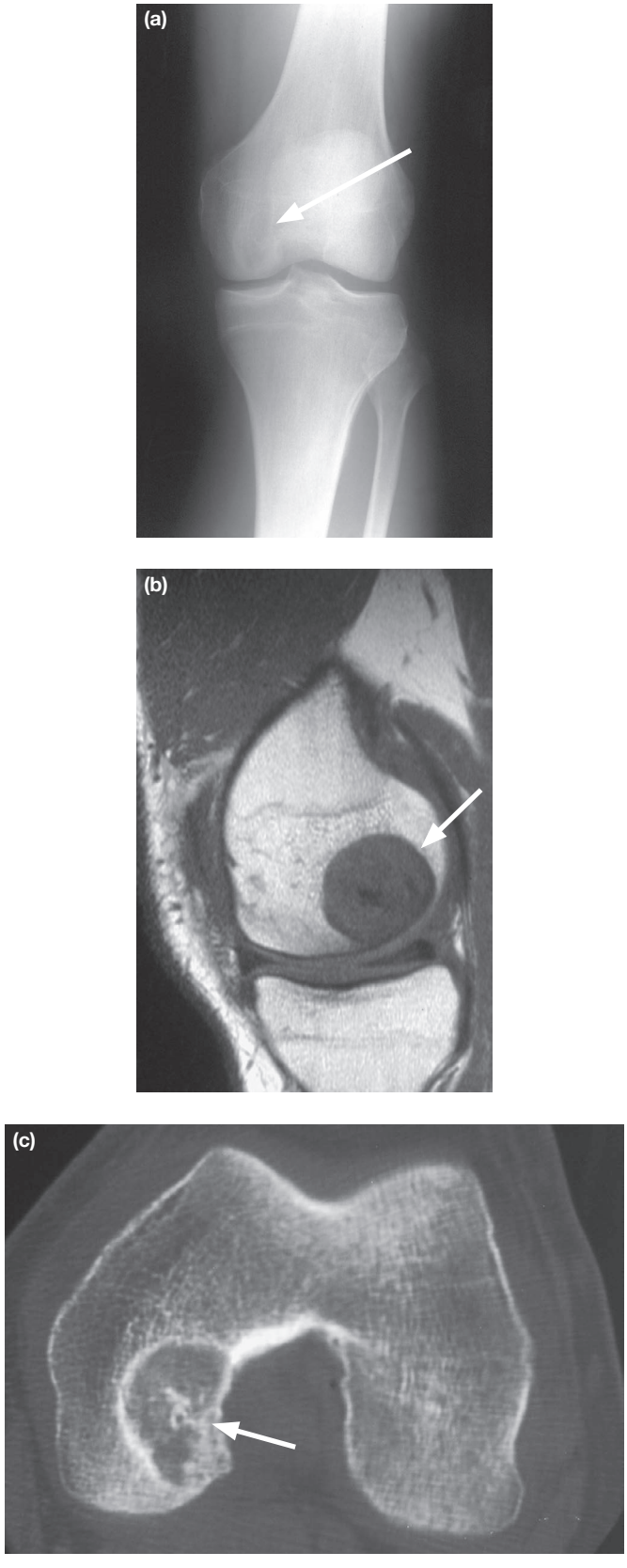

Figure 42.19 (a) Clear cell chondrosarcoma of the medial femoral condyle (arrow). (b) Sagittal T1-weighted magnetic resonance imaging scan showing a clear cell chondrosarcoma (arrow) in the medial femoral condyle. (c) Computed tomography scan reconstruction shows calcification (arrow) within the lesion.

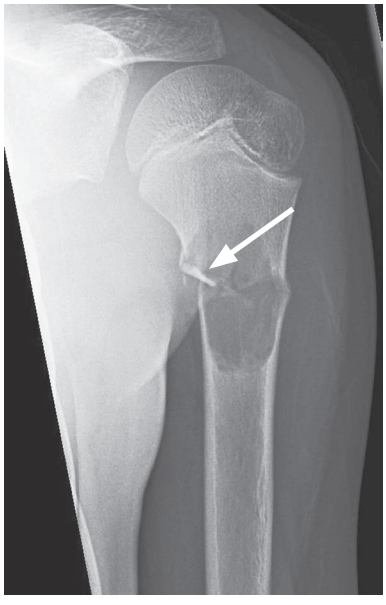

Figure 42.20 Pathological fracture through a simple bone cyst (arrow) with the pathognomonic fallen leaf sign. The fracture healed and the cyst consolidated without operative intervention.

Eosinophilic granuloma is a rare neoplasm of Langerhans cells (*Figure 42.23*). It can be unifocal (eosinophilic granuloma), multifocal (Hand–Schüller–Christian disease) or disseminated (Letterer–Siwe disease). There is a predilection for the skull and the diaphyses of long bones. In the spine it can present with collapse, known as vertebra plana. The radiographic appearance can be aggressive and similar to Ewing's sarcoma.

Fibrous dysplasia (*Figure 42.24*) is a benign, developmental, fibro-osseous lesion that can be mono- or polyostotic. It usually affects the long bones, ribs and skull. Patients can present with pain, swelling and/or fracture, but many lesions are detected incidentally. Hip fractures can produce a 'shepherd's crook' deformity of the proximal femur. Radiologically there is often expansion and a ground-glass appearance, sometimes with cystic change.

Ewing's sarcoma (*Figure 42.8*) is a malignant round cell sarcoma of bone in which cells usually have a characteristic 11:22 translocation. However, other mutations have been described. It tends to arise in the diaphysis of a long bone, pelvis or scapula. Patients usually present with a painful mass and may have systemic symptoms, including fever, anaemia and increased erythrocyte sedimentation rate (ESR). Radiologically the bone appears moth-eaten and may show an 'onion skin' periosteal reaction. MRI may show a large extraosseous soft-tissue mass as well as significant inflammation with oedema.

Bone tumours usually occur in characteristic anatomical locations (*Table 42.2*), and epiphyseal tumours are likely to be benign (*Table 42.3*).

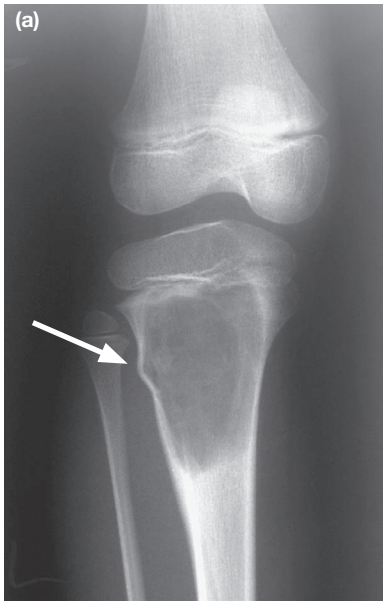

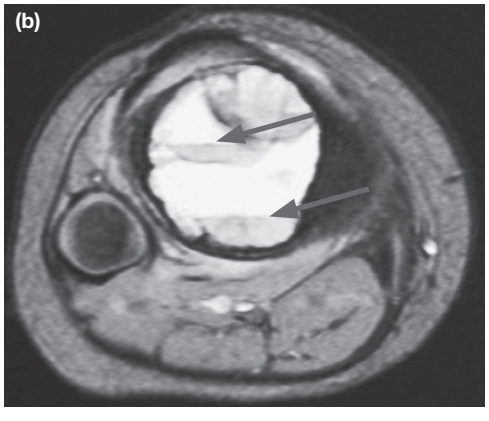

Figure 42.21 (a) Aneurysmal bone cyst with pathological fracture (arrow) of the proximal tibia. (b) Magnetic resonance imaging scan shows multiple fluid levels (arrows).

Figure 42.22 Giant cell tumour of the distal radius (arrow). Note the classic epiphyseal/metaphyseal location with subarticular involvement, as well as a permeative margin proximally in the radius indicating locally aggressive behaviour.

Paul Langerhans, 1847–1888, Professor of Pathological Anatomy, Freiberg, Germany.
Alfred Hand Jr, 1868–1949, American pediatrician, described the eponymous disease in 1893.
Artur Schüller, 1874–1957, Austrian neuroradiologist, described the eponymous disease in 1915.
Henry A Christian, 1876–1951, American physician, described the eponymous disease in 1919.
Erich Letterer, 1895–1982, German pathologist.
Sture A Siwe, 1897–1966, Swedish paediatrician.

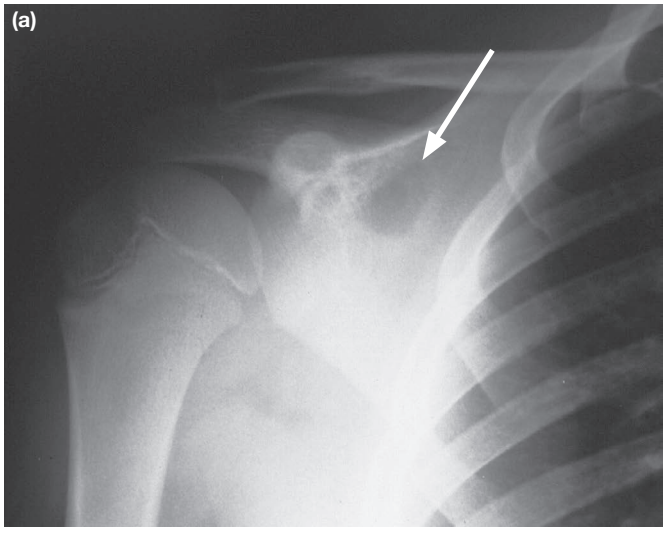

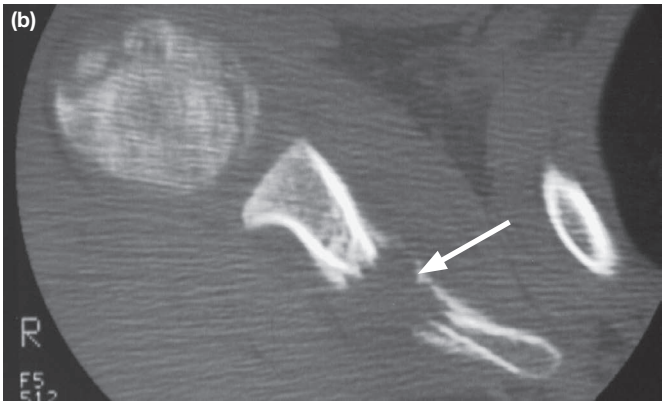

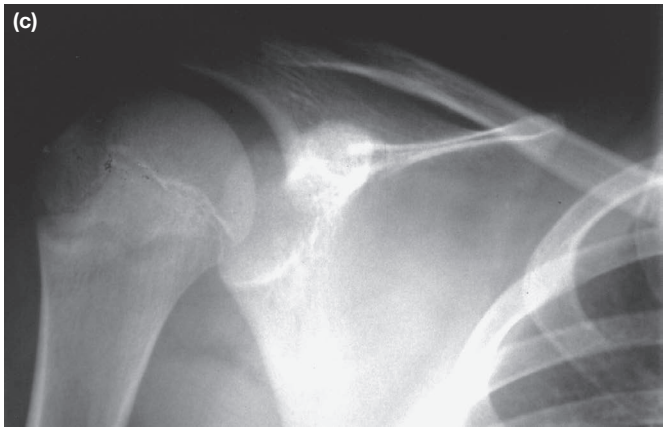

Figure 42.23 **(a)** Eosinophilic granuloma of the scapula (arrow). **(b)** Computed tomography scan shows a 'punched-out' lesion (arrow). **(c)** Spontaneous resolution.

TABLE 42.2 Classification of bone tumours by site.

Site	Tumour
Diaphyseal	• Eosinophilic granuloma • Osteoid osteoma • Fibrous dysplasia • Adamantinoma • Ewing's sarcoma
Metaphyseal	• Most
Epiphyseal	• Chondroblastoma • Intra-articular osteoid osteoma • Giant cell tumour (physis closed) • Clear cell chondrosarcoma

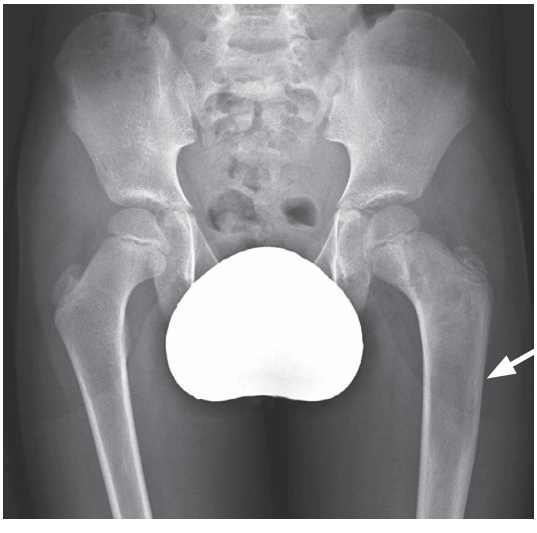

Figure 42.24 Fibrous dysplasia affecting the left proximal femur (arrow). There is expansion of the bone with a ground-glass appearance.

TABLE 42.3 Common diaphyseal bone tumours according to age.

Age	Most common diaphyseal tumour
<10 years	Eosinophilic granuloma
Teenage	Ewing's sarcoma
Adult	Lymphoma
>60 years	Metastasis/myeloma

Summary box 42.6

Other bone tumours

- Simple bone cyst – proximal long bones of children
- Aneurysmal bone cyst – more aggressive, expanding
- Giant cell tumour – found in epiphyses around the knee
- Fibrous dysplasia – may be multiple; long bones, ribs and skull
- Ewing's – round cell sarcoma; patients may have fever and anaemia

Staging of primary bone tumours

In the Enneking system, benign tumours are staged as:

- latent (e.g. osteochondroma);
- active (e.g. osteoid osteoma);
- aggressive (e.g. giant cell tumour).

William F Enneking, 1926–2014, American orthopedic oncologist.

Latent lesions are usually asymptomatic and often discovered incidentally. Active lesions, such as osteoid osteoma, present with mild symptoms and continue to grow. Aggressive lesions tend to grow rapidly and destroy bone.

The Enneking staging system for malignant tumours combines the local extent of the tumour and the histological grade (*Table 42.4*). The compartment is the bone in which the tumour arises. A tumour is extracompartmental when it has breached the cortex of the bone. Most primary malignant bone tumours are Enneking stage 2B at diagnosis, meaning they have extended outside the bone of origin but metastases are not detectable. The American Joint Committee on Cancer (AJCC)/Union for International Cancer Control (UICC) staging system is also widely used.

TABLE 42.4 The Enneking staging system for bone tumours.

Low grade	Intracompartmental	1A
	Extracompartmental	1B
High grade	Intracompartmental	2A
	Extracompartmental	2B
Any grade	Metastases	3

Summary box 42.7

Warning signs – bone tumour

- Non-mechanical bone pain
- Especially around the knee in young adolescents
- Concerning radiographs

SOFT-TISSUE TUMOURS

Soft-tissue tumours have also historically been classified according to their morphological appearance and presumed cell of origin. The range of biological behaviour is wide and most morphological types have a benign and malignant counterpart, for example lipoma (*Figure 42.25*) and liposarcoma. Other more frequent types include undifferentiated pleomorphic sarcoma and synovial sarcoma. Patients with suspected or confirmed soft-tissue sarcomas should be assessed and managed in a specialist centre.

Summary box 42.8

Warning signs – soft-tissue tumour

- Larger than 5 cm
- Increasing in size
- Painful
- Deep to the fascia
- Recurrence after previous excision

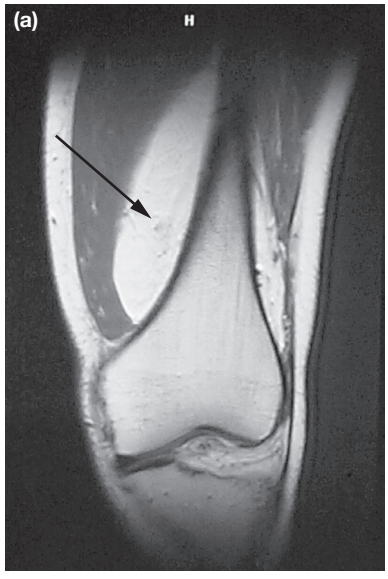

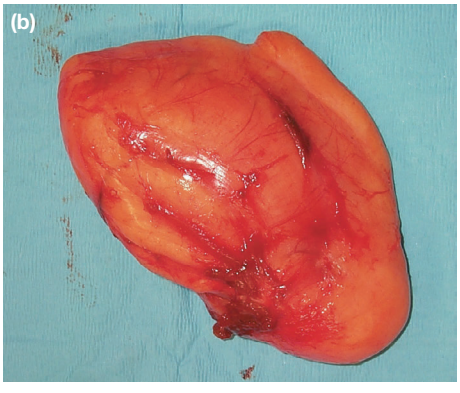

Figure 42.25 (a) Coronal T1-weighted magnetic resonance imaging scan showing a benign lipoma deep to the quadriceps muscle (arrow). **(b)** Excised benign lipoma.

The Trojani system, based on tumour differentiation, mitotic count and tumour necrosis, is the standard for grading malignant soft tissue tumours. The AJCC / UICC system is used to stage malignant soft tissue tumours.

EVALUATION AND INVESTIGATION OF THE PATIENT WITH A SUSPECTED BONE OR SOFT-TISSUE TUMOUR

The diagnosis and treatment of patients with primary bone and/or soft-tissue tumours requires a high index of suspicion, appropriate and prompt investigation, and early referral to a specialist multidisciplinary team for diagnosis, biopsy and appropriate treatment. When a musculoskeletal tumour is suspected, clinicians should:

- stop;
- think;
- investigate.

Monique Trojani, contemporary, described the histopathological grading system in 1984.

The assessment and investigation of any patient with a bone or soft-tissue tumour can be divided into three phases. The first two phases can be performed at the referring hospital, but the third phase may be best done in a specialist centre (*Table 42.5*).

TABLE 42.5 The three phases of assessment of lesions.

Phase 1 (within 24 hours)	Phase 2 (within first week)	Phase 3 (at specialist centre)
• History and examination • Blood tests • Radiograph whole bone • Chest radiograph	• Bone scan • Ultrasound scan abdomen • CT scan chest	• CT scan lesion • MRI scan lesion • Biopsy

CT, computed tomography; MRI, magnetic resonance imaging.

History and examination

It is important to take a thorough history, including a pain history. Non-mechanical and/or night pain, particularly in the young adolescent, is a concerning symptom and a primary bone tumour should be suspected. Relief with non-steroidal anti-inflammatory drugs may suggest an osteoid osteoma.

Patients with a history of malignancy who present with back pain should be considered to have metastatic bone disease until proven otherwise. Plain radiographs of the spine and routine blood tests are the minimum that is required. An MRI of the spine is a more sensitive test for the detection of a malignant tumour and may demonstrate soft-tissue extension into the spinal canal. Multiple myeloma (*Figure 42.3*) is the most common primary malignancy of bone in adults and should be considered in all patients over 65 years of age with back pain. Back pain associated with an ESR >100 mm/h indicates multiple myeloma until proven otherwise. Monoclonal gammopathy or elevated urinary and serum Bence Jones proteins are diagnostic. All patients with suspected cancer in the spine should be examined for signs of spinal cord compression, a potential surgical emergency.

Great care should be taken when managing a patient with an apparently 'solitary' bone metastasis. This could be a primary bone tumour, and further investigation including biopsy is required.

Soft-tissue tumours are common and the vast majority are benign. However, a soft-tissue mass meeting any of the following criteria may be malignant and the patient should be referred to a specialist centre:

- painful;
- increasing in size;
- more than 5 cm in diameter.

In addition, tumours that have recurred after previous excision and tumours located deep to the fascia are more likely to be malignant. It is important to note that tumours that appear mostly superficial but involve the deep fascia are classified as deep tumours.

Investigation

The investigation of a patient with a suspected primary bone or soft-tissue tumour should include the following.

- Local investigations:
  - ultrasound scan (for soft-tissue tumours);
  - plain radiographs of the whole affected bone or soft-tissue lesion (*Figure 42.1*);
  - MRI of the whole affected bone or soft-tissue mass;
  - computed tomography (CT) scan may be helpful in addition to an MRI scan.
- Distant:
  - blood tests, including full blood count, ESR, urea and electrolytes, bone profile and protein electrophoresis;
  - plain radiographs or CT scan of the chest (more sensitive);
  - whole-body isotope bone scan (for suspected primary or metastatic bone tumours);
  - ultrasound or CT scan of the abdomen (if renal metastasis is a possibility).

Plain radiographs are usually the most useful imaging investigations in determining the diagnosis of a primary bone tumour, but further appropriate scans are usually required for confirmation and staging. Imaging should always include the whole of the affected bone to look for satellite lesions and skip metastases. Satellite lesions occur within, whereas skip lesions occur beyond, the reactive zone of the tumour, which is the layer of compressed tissues, inflammatory cells and tumour infiltration that surrounds the tumour.

Both primary bone and soft-tissue sarcomas metastasise to the lungs, and a CT scan of the chest is an essential part of staging.

Patients who present with a lytic bone lesion could have a primary renal carcinoma and an ultrasound or CT scan of the abdomen is advised. Surgery to a renal metastasis can lead to significant blood loss.

Summary box 42.9

Staging

- Plain radiography is most informative for bone tumours
- Always image the whole bone in the case of skip lesions
- CT of the lung detects lung metastases
- Lytic lesions require imaging of the abdomen to check for a primary renal carcinoma

Biopsy

A biopsy is performed only when local staging investigations have been completed. Because removal of the biopsy track is an important principle in the treatment of sarcomas, and specialist pathology is required, biopsies should be performed either in, or after consultation with, the specialist centre where the definitive surgical procedure will be performed.

Henry Bence Jones, 1813–1873, physician, St George's Hospital, London, UK.

Image-guided biopsies (usually ultrasound- or CT-guided) have a higher diagnostic accuracy because areas of radiological concern can be targeted. If image-guided biopsy is performed, close discussion between radiologist and surgeon is required to ensure an appropriate biopsy route is used (*Figures 42.26 and 42.27*).

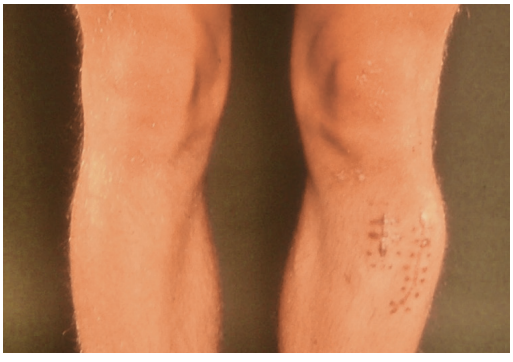

Figure 42.26 Poorly placed biopsies can make subsequent surgical excision of the track difficult or not possible.

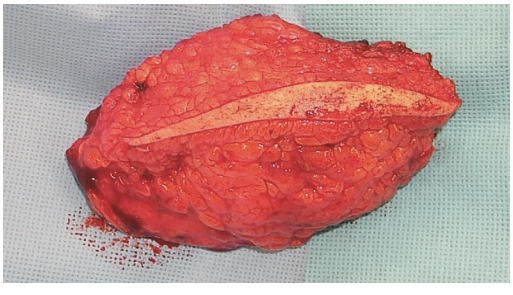

Figure 42.27 *En bloc* excised tumour and biopsy track.

Summary box 42.10

Biopsy

- Only biopsy once local staging is completed
- Biopsy should be performed at, or after discussion with, the specialist centre
- Image-guided biopsy is more reliable
- The biopsy track should be excised at definitive surgery
- Jamshidi needles for bone; Trucut needles for soft tissues

Biopsies for bone tumours are usually taken using a Jamshidi or other hollow needle (*Figure 42.28*), while Trucut needles are preferred for soft-tissue tumours.

Although most biopsies are performed with a needle, sometimes an open biopsy is required, which should be performed according to the following principles.

- A tourniquet can be used; but exsanguination by compression should be avoided as this may disseminate the tumour.

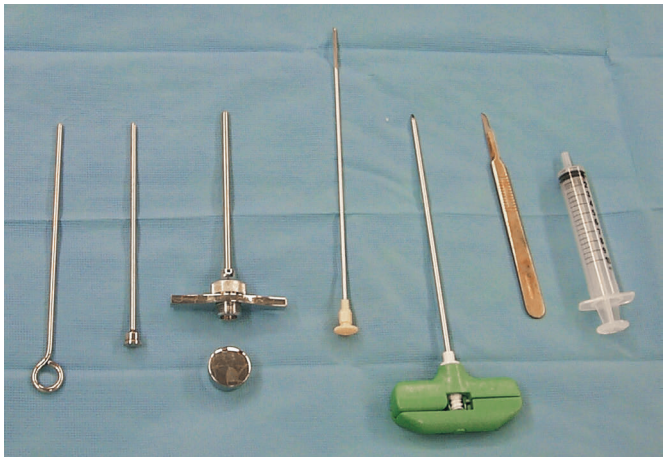

Figure 42.28 Bone biopsy instruments.

- Use longitudinal incisions that are part of an extensile approach.
- Do not cross anatomical compartments or contaminate critical anatomical structures (e.g. nerves or blood vessels).
- Use a biopsy track that can be excised at the time of definitive surgery.
- Ensure specimens are sent for microbiology as well as histopathology.
- Some specimens should be sent fresh to the laboratory for genetic studies.

PRINCIPLES OF TREATMENT

Primary bone tumours

Benign

Most latent and active benign bone tumours that need treatment are treated by intralesional curettage. Packing of the cavity with a graft or bone substitutes is usually not required.

Simple bone cysts can heal following pathological fracture and an initial conservative approach following fracture is best. If the cyst persists following union of the fracture, and the risk of further fracture is deemed to be high, then a variety of treatments, including injection with steroid or bone marrow and surgical curettage, have been described.

Osteoid osteomas can resolve spontaneously. However, symptoms are often pronounced, and most patients are treated by CT-guided thermocoagulation. Surgical removal (which usually requires burring down onto the surface of the nidus and removing it) is seldom required.

Large or more rapidly growing benign bone tumours may require more extensive surgical excision and reconstruction. Giant cell tumours of bone are associated with a high local recurrence rate and are usually treated with thorough curettage or, when very extensive, surgical resection of the affected bone. The RANK-ligand (receptor activator of nuclear factor ligand) antibody denosumab has an evolving role in treating these tumours.

En bloc is French for 'in a block'.
Khosrow Jamshidi, contemporary, Iranian haematologist.

Malignant tumours

Malignant primary bone tumours require a multidisciplinary approach that may include chemotherapy and radiotherapy as well as surgery. Osteosarcoma and Ewing's sarcoma are treated with neoadjuvant (before surgery) chemotherapy and surgery. Chondrosarcomas are not sensitive to chemotherapy or radiotherapy and treatment is surgical excision where possible.

The aim of surgery for a primary malignant bone tumour is to remove it completely (usually with a layer of normal tissue around it that includes the biopsy track) and then to reconstruct the limb to maximise physical function.

Following excision the surgical margins can be classified as shown in *Table 42.6*.

TABLE 42.6 Classification of surgical resection margins.

Intralesional	Resection through the tumour
Marginal	Resection through the reactive zone of the tumour
Wide	Resection outside the reactive zone of the tumour
Radical	Resection of the whole anatomical compartment

In most cases, limb salvage with excision and reconstruction is possible (*Figure 42.29*). Only a minority of patients (10–15%) require primary amputation, either because of neurovascular invasion or because the reconstructed limb may be less functional than an amputation (e.g. for some tumours in the foot and ankle). Limb salvage is associated with a slightly higher rate of local recurrence than amputation. However, no difference in overall survival has been demonstrated. The surgical options for malignant primary bone tumours include:

- amputation or van Nes rotationplasty;
- excision alone (for dispensable bones, e.g. the fibula, or areas where reconstruction is difficult, e.g. in parts of the pelvis);
- excision and reconstruction with a structural graft or massive endoprosthesis.

The complications of massive endoprosthetic reconstruction of a limb include infection, instability and wear or loosening of the prosthesis.

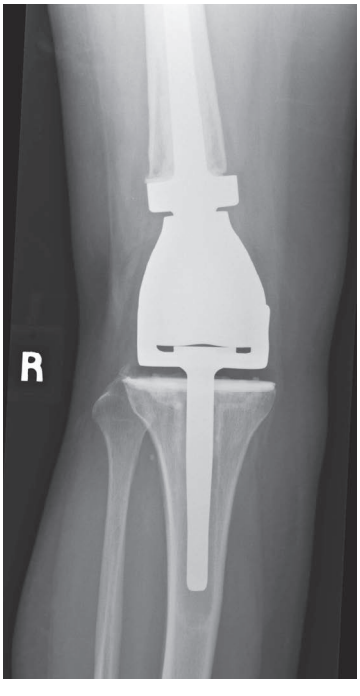

Figure 42.29 Endoprosthetic replacement of the distal femur.

Summary box 42.11

Treatment of benign bone tumours

- Benign lesions can usually be simply curetted
- CT-guided thermocoagulation is used for osteoid osteoma
- Large benign tumours may require reconstruction

Summary box 42.12

Treatment of malignant bone tumours

- Osteosarcomas and Ewing's sarcoma require neoadjuvant chemotherapy
- Chondrosarcomas are insensitive to radiotherapy or chemotherapy
- Most malignant tumours can be treated with limb salvage
- There is no difference in survival between amputation and limb salvage

Metastatic bone disease

Patients with confirmed metastatic bone disease may require resuscitation for electrolyte imbalance, anaemia, cardiorespiratory problems or hypercalcaemia before surgical treatment can be considered. Hypercalcaemia can be treated effectively with fluid resuscitation and bisphosphonate infusion.

Surgical treatment in patients with metastatic bone disease is usually palliative; although complete resection of solitary metastases in selected patients may confer some survival benefit, the evidence for this is not strong.

Surgery of the spine may be required for stabilisation and/or decompression when tumour extension puts the spinal cord at risk. Surgery in the peripheral skeleton is mainly for treatment of pain and (impending) pathological fracture.

Renal metastases tend to be very vascular and massive blood loss can be encountered during surgery. Therefore, preoperative embolisation should be considered just before surgery to prevent blood loss (*Figure 42.30*).

Treatment of myeloma is mainly haematological. Nonsurgical treatments including radiotherapy can lead to healing

Cornelis Pieter van Nes, 1897–1972, Dutch orthopaedic surgeon, who practised in Leiden and described rotationplasty in 1950.

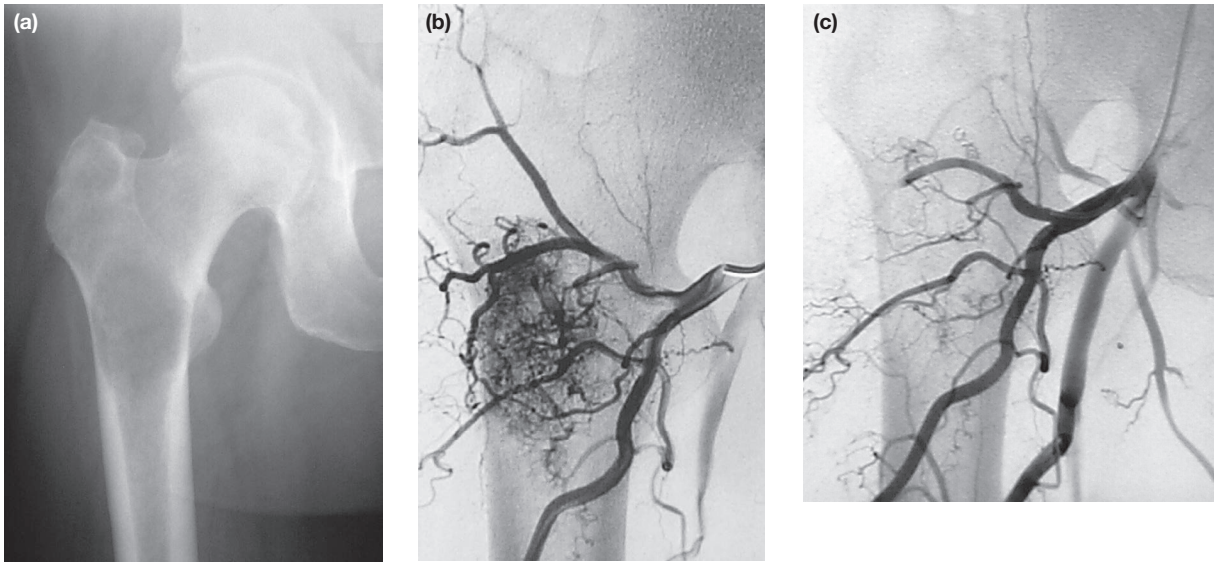

Figure 42.30 (a) Lytic metastasis of renal cell carcinoma. **(b)** Angiogram shows increased vascularity. **(c)** Following embolisation.

of bone lesions in some cases. Surgical treatment is often required for complications such as fracture and spinal cord compression.

The following factors should be considered when contemplating surgical treatment for patients with metastatic bone disease:

- likely survival (*Figure 42.31*) – consider the primary diagnosis and performance status;
- quality of life;
- fitness for anaesthesia and surgery;
- fracture risk;
- single or multiple bone lesions;
- response to adjuvant treatment such as radiotherapy and hormonal treatment;
- radiotherapy can be administered pre- or postoperatively.

The risk of pathological fracture can be assessed using the Mirels score (*Table 42.7*). However, this scoring system is prone to inter- and intraobserver variation.

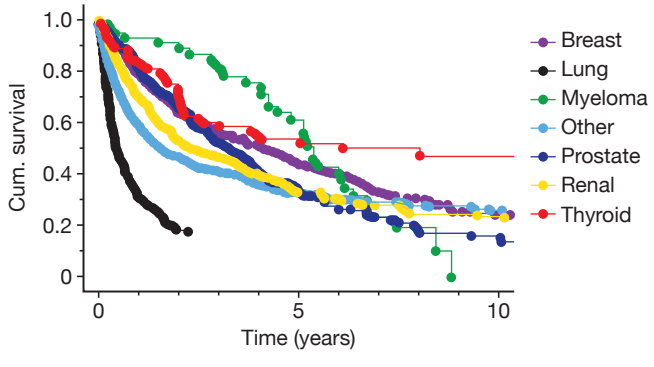

Figure 42.31 Cumulative survival curves of patients who present with bony metastasis.

TABLE 42.7 The Mirels scoring system for risk of pathological fracture.

	Score		
	1	2	3
Site	Upper limb	Lower limb	Peritrochanteric
Pain	Mild	Moderate	Functional
Size	<1/3	1/3–2/3	>2/3
Lesion	Blastic	Mixed	Lytic

Score >8, high risk of fracture – urgent prophylactic fixation should be considered; score <8, low risk of fracture – orthopaedic intervention may not be required.

Bone healing following a fracture through a metastasis is unpredictable and there can be local recurrence of the tumour after treatment. The approach is therefore different from the treatment of other fractures. The aim of surgery should be to improve pain and maintain mobility. Approaches that require prolonged protected weight-bearing to allow healing are not appropriate in this group of patients with reduced life expectancy. Therefore, as a general rule, prosthetic replacement of bones is preferred, particularly for epiphyseal and metaphyseal lesions. Metastases in the diaphysis may be most appropriately treated with an intramedullary nail. In the shoulder, prosthetic replacements have a poor function and internal fixation may give better physical functioning. However, for hip lesions, the best treatment is often replacement surgery.

Patients with solitary breast and renal metastases can have prolonged disease-free survival, so excision and replacement rather than fixation should be considered.

Hilton Mirels, contemporary, South African orthopaedic surgeon who now practises in the USA.

Summary box 42.13

Treatment of bone metastases

- Surgery cannot lengthen life but may shorten it
- The spine may need to be stabilised and nerves or the cord decompressing
- Long bones will need to be stabilised if a pathological fracture is imminent
- Patients who have a possibility of long-term survival may need excision and prosthetic reconstruction
- Radiotherapy often relieves pain

Soft-tissue tumours

The treatment of soft-tissue tumours should take account of tumour type and the response to other treatments including radiotherapy. Large low-grade or benign lipomatous tumours may be excised in a deliberately marginal or close but complete fashion. Soft-tissue sarcomas should however be excised with a margin of normal tissue around them, which includes the biopsy track, wherever possible (***Figure 42.27***). Skin involvement may require resection of the skin and reconstruction with a split-skin graft or skin flap.

Following surgical excision of high-grade soft-tissue sarcomas, adjuvant radiotherapy should be considered. Preoperative radiotherapy can also have good results, but there is a risk of wound-healing problems following surgery. Chemotherapy has a limited role in the treatment of soft-tissue sarcomas.

FURTHER READING

British Orthopaedic Oncology Society and British Orthopaedic Association. *Metastatic bone disease. A guide to good practice*. Oxford: BOOS; London: BOA, 2015.

Cool P, Grimer R. Pathological fractures of the extremities. *Trauma* 2000; **2**: 101–11.

Cool P, Grimer R, Rees R. Surveillance in patients with sarcoma of the extremities. *Eur J Surg Oncol* 2005; **31**(9): 1020–4.

Dangoor A, Seddon B, Gerrand C *et al*. UK guidelines for the management of soft tissue sarcomas. *Clin Sarcoma Res* 2016; **6**: 20.

Enneking WF, Spanier SS, Goodman MA. A system for the surgical staging of musculoskeletal sarcoma. *Clin Orthop Relat Res* 1980; **153**: 106–20.

Gerrand C, Athanasou N, Brennan B *et al*. on behalf of the British Sarcoma Group. UK guidelines for the management of bone sarcomas. *Clin Sarcoma Res* 2016; **6**: 7.

Mankin HJ, Lange TA, Spanier SS. The hazards of biopsy in patients with malignant primary bone and soft tissue tumors. *J Bone Joint Surg* 1982; **64-A**: 1121–7.

Mirels H. Metastatic disease in long bones. *Clin Orthop* 1989; **249**: 256–64.

Wedin R, Bauer HC. Surgical treatment of skeletal metastatic lesions of the proximal femur: endoprosthesis or reconstruction nail? *J Bone Joint Surg Br* 2005; **87**(12): 1653–7.

World Health Organization, International Agency for Research on Cancer. *WHO classification of tumours*. Vol. 3. *Soft tissue and bone tumours*, 5th edn. Lyon: IARC Press, 2019.

Union for International Cancer Control. *TNM classification of malignant tumours*, 8th edn. Oxford/Hoboken, NJ: John Wiley & Sons, 2017.